

Forensic Odontology: Introduction and Recent Advances

Dr. Rahul Gupta¹; Dr. Shivam Sahney²

Interns

Subharti Dental College and Maxillofacial Hospital, SVSU

Meerut, U.P., India

rahulguptameerut@gmail.com ; shivamsahney786@gmail.com

ABSTRACT

Forensic Odontology is a great study and science which is very important these days due to increasing medico-legal matters as well as situations in which a dead body found is to be identified. This area of dentistry is evolving very much these days. We know that whenever a dead body is found whether decomposed or burnt, the significant thing to notice is that dental tissues are many times remain preserved. Hence, this Odontology science is very much applied in mass calamities, disasters, sexual assault, etc. cases. Since, we know that it is so much important and the data collection methods and analysis are transforming day by day, so, there is a need to update about the newer technologies, methods and concepts. Hence, this chapter will help the practicing and the participating dentists to be updated on the newer transformation incorporated and used in Forensic Odontology.

Keywords--- Forensic; Odontology; Dentistry; Advances; Methods

CONTENTS

- INTRODUCTION
- BASICS OF FORENSIC ODONTOLOGY
- IDENTIFICATIONS IN FORENSIC ODONTOLOGY
- LIMITATIONS OF FORENSIC ODONTOLOGY
- EXPERTISE OF FORENSIC DENTISTS
- CONVENTIONAL METHODS
- RECENT ADVANCEMENTS AND METHODS
- CONCLUSION
- REFERENCES

I. INTRODUCTION

Forensic Odontology, an evolving branch of dentistry these days has derived its name from Latin i.e. Forensic in Latin means “to the forum”. According to Keiser-Neilson, Forensic Odontology is “that branch of forensic medicine which in the interest of justice, deals with the proper handling and examination of dental evidence and also with proper evaluation and presentation of the dental findings”.

We know that teeth are the hardest dental tissue and can resist exposure of severe situations. Further, every individual on this planet has a unique dental pattern and unique dental treatment modalities done in past, therefore, these uniqueness in our teeth help in individual identification by matching the ante-mortem and the post-mortem records. Hence, it’s a great tool for the identification of the dead body founded in disasters, crimes or accidents. Since many years, Forensic Odontology field has helped the court to solve criminal cases by providing matched dental evidences.

Most importantly, Forensic Odontology has three major areas of utilization namely:

- Diagnostic and therapeutic examination and evaluation of injuries to jaws, teeth and oral soft tissues,
- The identification of individual, especially casualties in criminal investigations and/or mass disasters,
- Identification, examination, and evaluation of bite marks which occur with some frequency in sexual assaults, child abuse cases, and in personal defence situations.

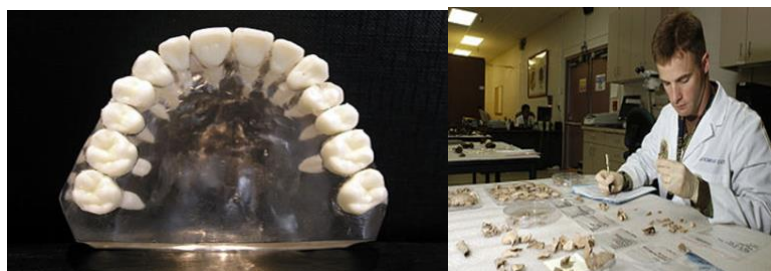

Figure 1: Diagnostic examination, identification and evaluation of the records

II. BASICS OF FORENSIC ODONTOLOGY

Forensic Odontology basically deals with post-mortem identification, based on recognition of unique features present in individual's oral structures. It plays a major role in identification in man-made or natural disasters, the events which result in multiple fatalities that may not be identifiable by only visual recognition.

Forensic Odontology relies on sound knowledge about the teeth and jaws and incorporates dental anatomy, histology, radiography, pathology, and dental materials.

Forensic Odontologists delve in the following:

- Identification of human remains by comparing post-mortem and ante-mortem records.
- Assist at the mass disaster site as well as individual identification.
- Eliciting the ethnicity affinity and assisting in building up a picture of lifestyle and diet of skeletal remains at forensic and archaeological sites.
- Assessing the sex of skeletonised remains.
- Estimating age whether living or dead.
- Bite mark investigation and analysis of bite mark found on foodstuff, human or animal tissue, etc.
- As an Expert Witness to present all the evidences before the court of law.

In the interesting history of Forensic Odontology, there have been many big cases in which the body of great leaders or celebs were identified. Counting a few examples from the history of Forensic Odontology:

- Raja Jai Chand, The King of Kannauj,
- Former Prime Minister of India, Rajiv Gandhi,
- Adolf Hitler, and so on.

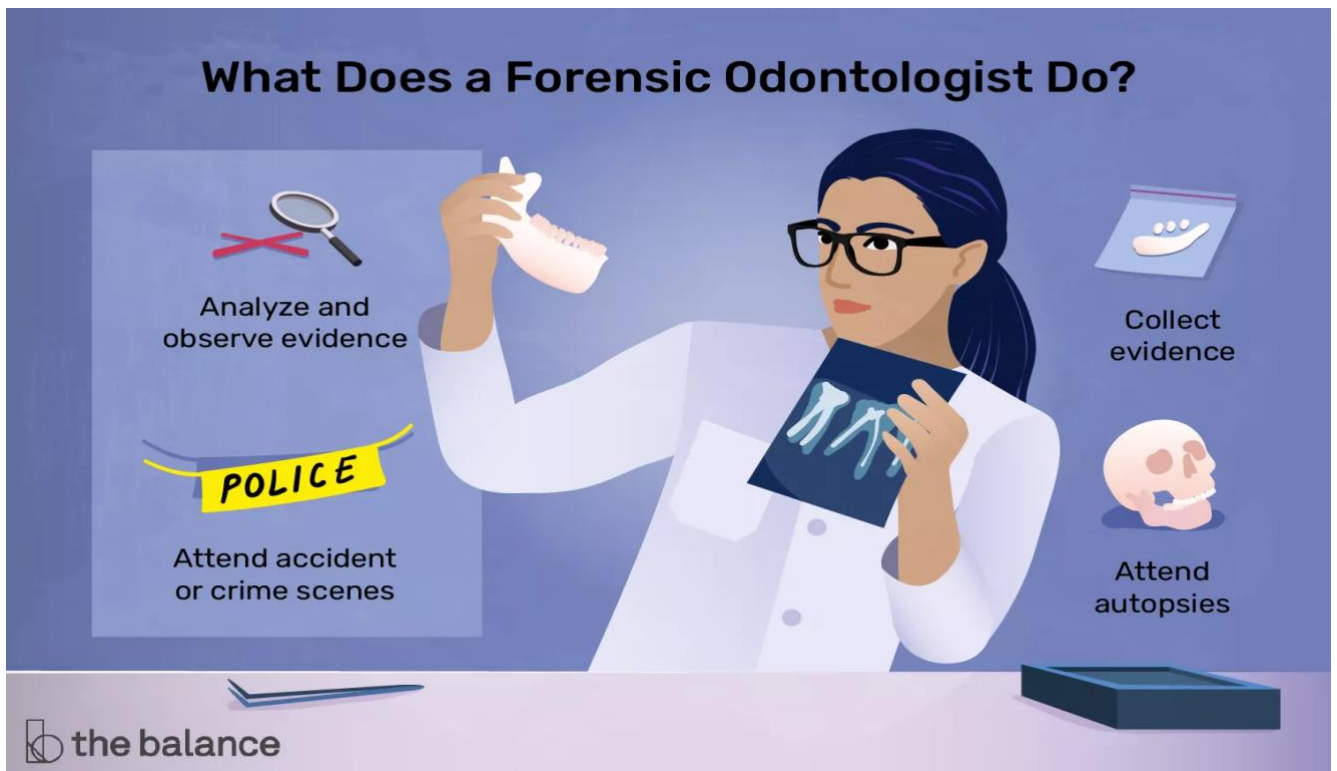

Figure 2: Basics of Forensic Odontology

III. IDENTIFICATIONS IN FORENSIC ODONTOLOGY

The most significant types of identification which are very significant in the field of Forensic Odontology. Enumerating the identifications in this field are:

- Personal Identification
- Dental Identification

A. Personal Identification

Personal identification is done to establish person's individuality. This identification is helpful in cases in which there is property issues, while insurance cases, when it has to be decided whether body is to be cremated or buried, etc.

It is done by visual recognition and the body's belongings. Since, these methods are not much reliable and is very traumatizing for family members therefore, it's approach now is different. Now a days the forensic experts choose a scientific means of identification by analysing the physical features of the dead body. Features like scars, dental restorations, etc are some acquired features which are also very helpful in personal identification.

As we know teeth are dental hard tissues which are one of the strongest part of the body, hence, these are very helpful to identify the dead bodies which are burnt or decomposed.

B. Dental Identification

It is one of the most essential identification method. The dental identification can be divided into:

- Comparative Dental Identification
- Reconstructive Dental Identification also known as Dental Profiling.

i) Comparative Dental Identification

Comparative dental identification comes under conventional methods of post mortem dental identification. It goes through four steps:

Step 1: Oral autopsy

Step 2: Obtaining dental records

Step 3: Comparing post and ante-mortem dental data

Step 4: Writing a report and drawing conclusion

Step 1: Oral Autopsy

In autopsy the dissection of the body is done. But in oral autopsy, it starts from external examination till the internal examination by dissection. Oral autopsy is challenging many a times as it may cause much of the post-mortem alterations, hence, it is critical enough. In oral autopsy, many samples of dental hard and soft tissues are taken. Most importantly each and every information must be entered in the odontogram or dental form for the records.

Step 2: Obtaining dental records

These are the records which states that in the past what type of treatment the person whose dead body is present has undergone. These records are taken into account as ante-mortem records while comparing. These records contain statements or documents such as dental radiographs, dental charts, photographs, etc. Hence, these also should be updated in the odontogram in a chronological order.

Step 3: Comparing post and ante-mortem dental data

The ante-mortem and post-mortem records collected so far are now at the step or stage to be compared within. These are compared with the help of ante-mortem and post-mortem odontograms. If the individual to be identified has undergone many treatments in the past, it becomes much easy for a forensic dental expert to identify the individual. The comparison done by the forensic dental expert should be qualitative not quantitative. As it is stated by Acharya and Taylor "Single point of concordance between post and ante-mortem data may be sufficient to establish identity, considering, of course, the uniqueness of such a feature and circumstances of the case."

Step 4: Writing a report and drawing conclusion

As we know that these Comparative Dental Identification documented are to be kept in front of the law enforces and justice panel, therefore, the documentation should be built with facts and with detailed comparison reports. Before keeping it in front of law enforces and legal authorities one should check the quality of the comparison as well as how much is the comparison significant. After this the final conclusion can be made which can be of four types:

- Positive Identification
- Probable Identification
- Possible Identification
- Excludes Identification
- Insufficient Identification

Positive Identification

This indicates that the ante- and post-mortem dental data match each other. The identity is proven 'beyond reasonable doubt' and much include post- and ante-mortem radiographs.

Probable Identification

There is a high level of concordance between the two sets of data, but may lack radiographic support. The data is consistent but a lack of quality post and/or ante-mortem information implies that one cannot confirm identity.

Possible Identification

The post and ante-mortem data are in agreement, but the available information is insufficient, usually in terms of quality. The available information neither permits a definitive identification nor enables the identity to be excluded.

Excludes Identification

The post and ante-mortem data are clearly inconsistent. The data contains unexplainable differences which comprehensively indicate a mismatch.

Insufficient Identification

The available post and ante-mortem information is minimal or insufficient to draw any conclusion on the identity of the deceased.

ii) Reconstructive Dental Identification

In Reconstructive Dental Identification, the population origin, sex and age known as the triad of information of the deceased is extracted.

The population origin or the ethnicity of the individual is extracted by admiring the shape, number of cusps of teeth, etc of the individual. As the individuals are divided into three races- Caucasoid, Mongoloid and Negroid. The individuals are classified according to the geographical origin. So, different races have different morphology of teeth.

Then, secondly the sex of the individual is assessed. It is done on the basis of admiring the morphology of skull, mandible, the size as well as shape of the teeth and most importantly by the analysis of dental DNA. The dimensions of skull, teeth size, etc are always measured.

Then, at the last of the triad, the age of the individual is estimated. To estimate the individual's age the teeth are considered more reliable than the individual's bone. The dental age is estimated under three groups or phases of teeth: (i) Prenatal, neonatal and early postnatal period, (ii) Children and adolescents, (iii) Adults.

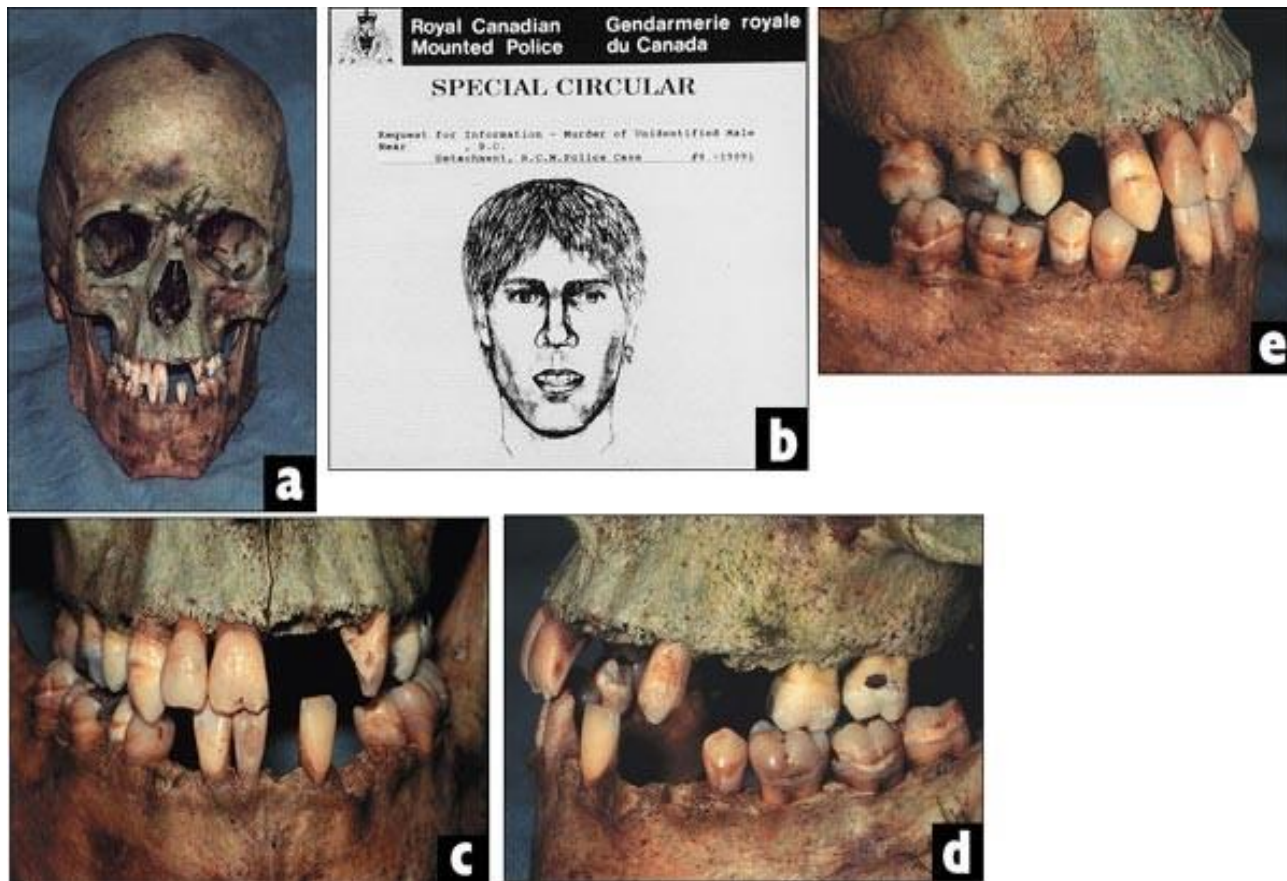


Figure 3: Dental Profiling

IV. LIMITATIONS OF FORENSIC ODONTOLOGY

Forensic Odontology is a very helpful tool or field when it comes to identification of dead bodies, still this field has some limitations which restrict it in certain cases. The limitations admired are:

- If the ante-mortem records of the deceased are not available, then post-mortem identification is not possible.
- There is a limitation of storing dental records for a certain period.
- Sometimes the dental records to be matched are not in good condition.
- In cases of burnt dead body, the fire may have altered the restoration which could have been taken into consideration while comparing the dental records.
- Taking palatal rugae in consideration, the one who had worn denture in past may have altered rugae pattern.
- While taking the lip print record, it should be collected within 24 hours from the time of death, otherwise there will be post-mortem alteration of lip.
- In cases of bite marks, the bite mark pattern on both the living or dead changes within 10-20 minutes most probably.

V. EXPERTISE OF FORENSIC DENTISTS

There is a difference between a “Dental Expert” and a “Forensic Dental Expert”. The dental expert has a knowledge which help him to just become an excellent witness only in dental matters but the forensic dentist has to become an expert witness in the matters related to crime and criminal investigations, hence, he has to gain an extra additional knowledge and experience. Therefore, a forensic dentist must have a recognised qualification and/or board certification as the court may ask for it.

Knight and Clark commented for forensic dentists that they should dress well in the court which will reflect their professional persona. Knight and Clark also warned that the temptation to become too partisan must be resisted, as a biased or angry witness is a careless and vulnerable witness, easily led into traps. It is always advised to forensic dentist witnesses in the court to keep their temper in control and remain calm.

The post-mortem reports, age estimation reports and other such records kept in front of court are the signed statement documents, hence, while cross questioning if there is a change in the opinion of Dental Expert witness then the opposing lawyers can

render the dental expert fallible. Therefore, dental expert witness should present his documents based on facts. In short, the Forensic Odontologist must be professional, ethical, unbiased and truthful in his facts.

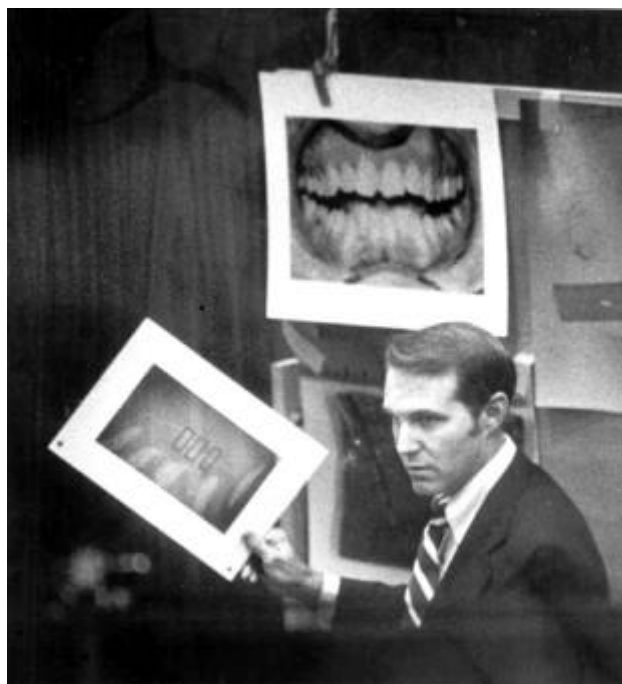

Figure 4: Forensic Dental Expert Witness

VI. CONVENTIONAL METHODS

Whenever a dead or deceased body is found, on general basis relatives are shown the body, who identify the body by looking for some characteristics such as their face, body shape or some of the personal belongings. But sometimes the problem arises in identification, since, the body has many times undergone post-mortem causing changes in body such as decomposition, therefore, this visual recognition method may be subjected to error.

Next method in the queue of conventional methods is the checking of personal and medical information. Personal information includes age, height, build, presence or absence of hair, etc. On the other hand, medical information includes any birthmark, scars, tattoos, any implant or prosthesis, etc. Footprint records can also be taken into account. DNA profiling and dental identification is also important while talking about the conventional methods. So, these methods and techniques conclude the queue of conventional methods.

VII. RECENT ADVANCEMENTS AND METHODS

In the past few years, the conventional data collection methods and analysis of data have been transformed. New one updated need to be known by us, therefore, the Recent Advances in Forensic Odontology are:

- DNA Analysis
- Facial Reconstruction
- Denture Identification
- Comparison Microscope
- Tongue Prints

These new methods and techniques have transformed the field of Forensic Odontology.

A. DNA Analysis

One of the new and significant tool in forensic odontology is the DNA Analysis. The best thing about it is that it reveals the genetic makeup of an individual. The biological samples taken for DNA typing are blood, teeth, hair, semen, bones, saliva, etc. The main substance used for DNA fingerprinting can be genomic and mitochondrial DNA. But according to studies, the best material for DNA typing are teeth.

There are various ways of extracting DNA from teeth are:

- Conventional Endodontic Access
- Vertical Splitting
- Horizontal Section
- Crushing
- Cryogenic grinding

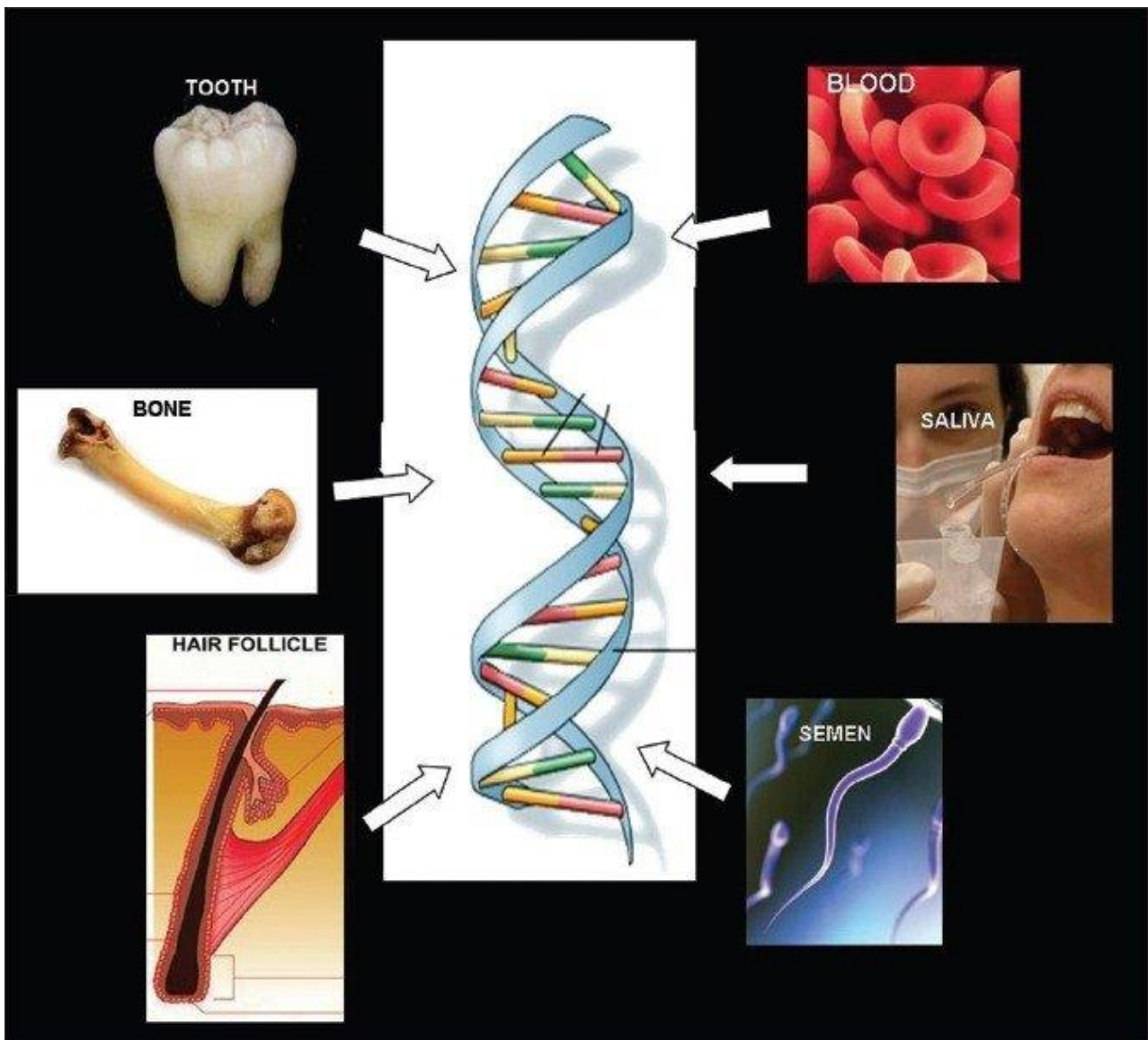


Figure 5: Samples for DNA Analysis in Forensic Odontology

B. Facial Reconstruction

Even the forensic artists use the dental profile for reconstruct the individual's face. It is important to reconstruct the face as it also helps to determine the individual's sex as well as it is helpful in cases where post-mortem records does not match the tentative identity of the deceased.

The facial reconstruction is done with the help of computer. The Laser video camera is a tool which help in building the computerised 3D facial reconstruction. Computer takes it as a data which is then converted into image with the help of a software. One example of the 3D facial reconstruction software is Vitrea 2.3 version volumetric visualization software. Not only computerised method, there is also a manual method present for the facial reconstruction.

But the limitation with the Facial reconstruction is that it is technique sensitive and an excellent skilled individual is needed to operate and interpret the facial reconstruction images.



Figure 6: Manual method of facial reconstruction

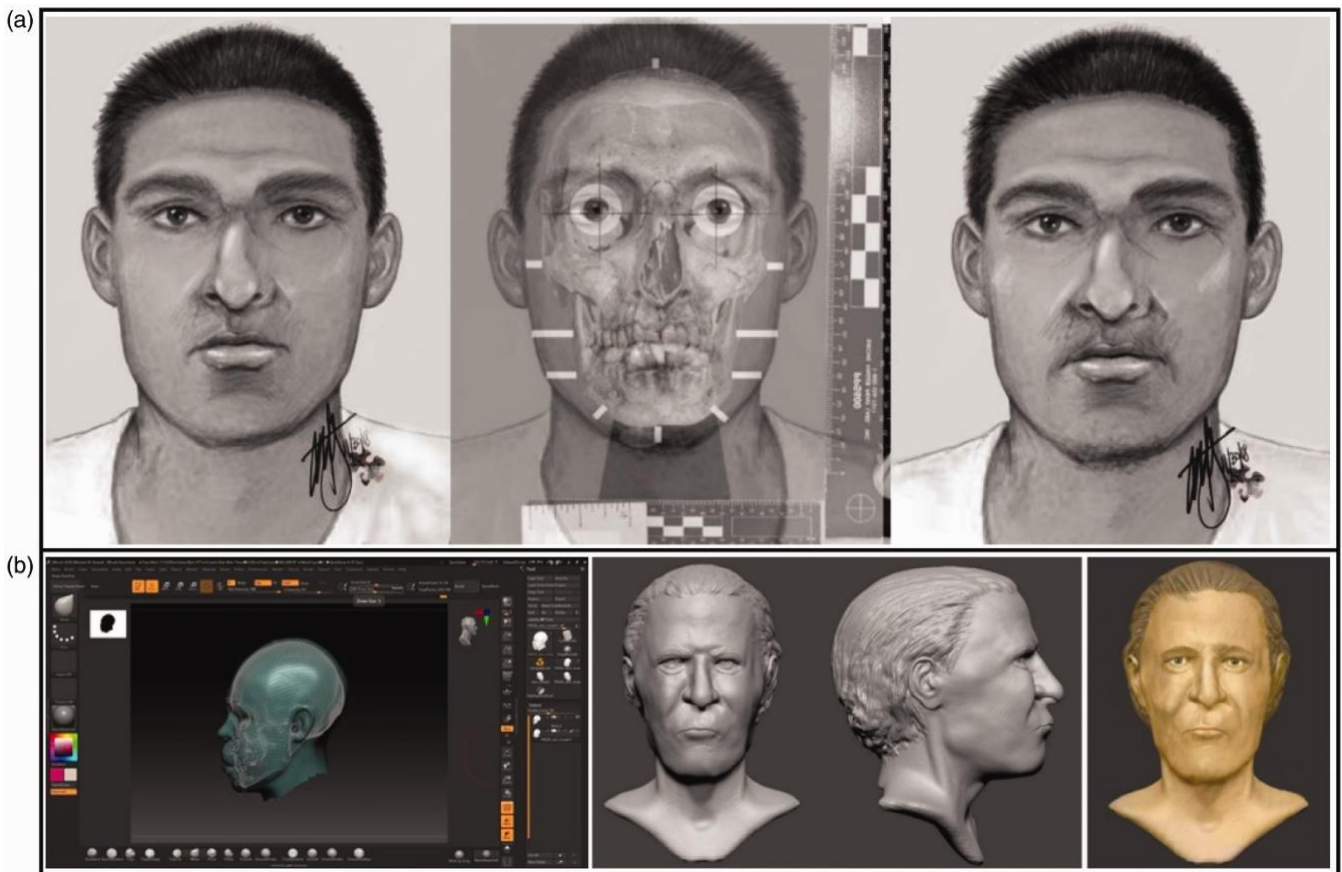


Figure 7: Computerised Facial Reconstruction

C. Denture Identification

This new method induced is for the individual who is edentulous. The most important criteria for this method is that the denture should be marked otherwise it is of no use for denture identification method. Labelling is done by the surface marking method or the inclusion method.

In the surface marking method, labelling is done by engraving or scribbling, on the other hand, the labelling of the denture in the inclusion method is done by computer printing or lead paper. So, this marking or labelling is helpful in keeping denture record and comparison of records.

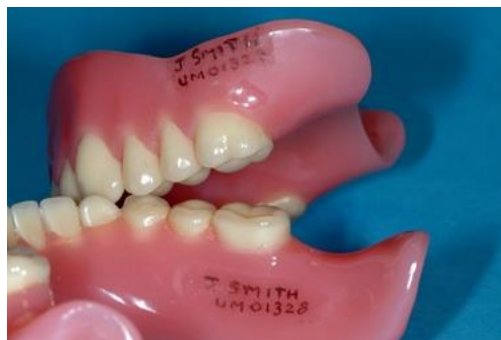

Figure 8: Surface Marking method

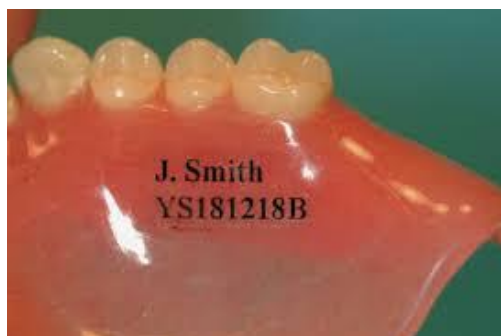

Figure 9: The Inclusion Method

D. Comparison Microscope

It is a helpful tool for analysing the specimens collected. The new tool developed by the forensic technology is known as Virtual Comparison Microscope (VCM). It has two microscopes connected to each other with the help of the optical bridge, containing a split view window. The system used by it is the Bullet Trax-3d system.



Figure 10: Comparison Microscope

E. Tongue Prints

Tongue morphology is unique for each and every individual. For this technique to be successful, the antemortem photograph or impression of the tongue should be available. The lingual impression together with its photographic image may constitute secure methods for forensic dentistry identification, in addition to rugoscopy and cheiloscopy.

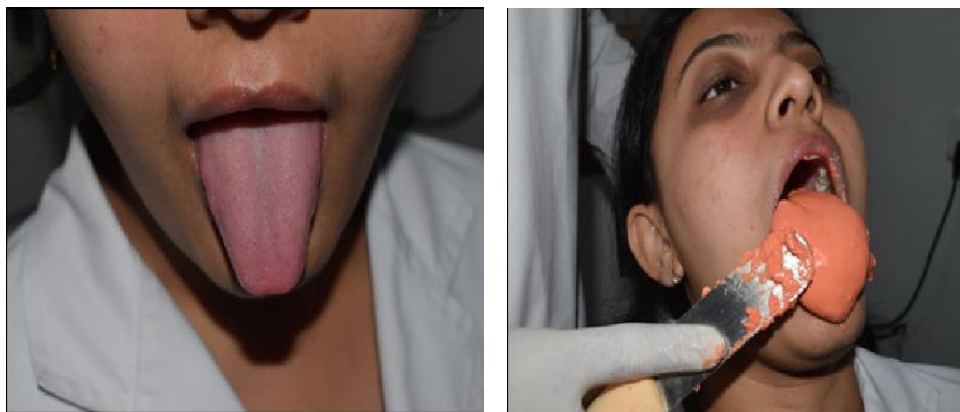


Figure 11: Tongue Print

VIII. CONCLUSION

Forensic Odontology is one of the upcoming branch of dentistry. Its all about the dental knowledge a forensic dental expert has. Teeth are least prone to destruction, hence, these are used in cases related to identification. It is most helpful in medicolegal investigations. Its an integral part of dental sciences. It is important to update every participating and practicing dentists about the current and advanced technologies coming in Forensic Odontology.

IX. REFERENCES

- [1] Forrest, Alex. "Forensic odontology in DVI: current practice and recent advances. Forensic sciences research 4.4 (2019): 316-330
- [2] sivapathasundharam, B., and Arya Rajendran. Shafer's textbook of oral pathology. Elsevier Health Sciences, 2012.
- [3] Jeddy, Nadeem, Shivani Ravi, and T. Radhika. "Current trends in forensic odontology." Journal of forensic dental sciences 9.3 (2017): 115.
- [4] Kavitha B, Einstein A Sivapathasundharam B, Saraswathi T. Limitations in forensic odontology. Journal of forensic dental sciences. 2009 Jun 1:08-10.
- [5] Verma, Anoop K., Sachil Kumar, Shiuli Rathore, and Abhishek Pandey. "Role of dental expert in forensic odontology." National journal of maxillofacial surgery 5, no 1 (2014): 2.
- [6] Singh, Narendra Nath, Owais Gowhar, Tasneem S. Ain, and Saima Sultan. "Exploring trends in forensic odontology." Journal of clinical and diagnostic research: JCDR 8, no. 12 (2014): ZC28.
- [7] Anoop K. Verma, Sachil Kumar, Sandeep Bhattacharya, Identification of a person with the help of bite mark analysis, Journal of Oral Biology and Craniofacial Research, Volume 3, Issue 2, 2013, Pages 88-91, ISSN 2212-4268,

- [8] https://en.wikipedia.org/wiki/Forensic_dentistry
- [9] <https://www.liveabout.com/forensic-odontologist-career-profile-974646>
- [10] Pretty, I., Sweet, D. A look at forensic dentistry – Part 1: The role of teeth in the determination of human identity. *Br Dent J* 190, 359–366 (2001). <https://doi.org/10.1038/sj.bdj.4800972>
- [11] Johnson, Abraham. “A Morphological Study of Tongue and its Role in Forensics Odontology.” (2018). <https://api.semanticscholar.org/CorpusID:90380511>
- [12] Jayanandan, Muruganandhan & Gopalakrishnan, Sivakumar. (2011). Practical aspects of DNA-based forensic studies in dentistry. *Journal of forensic dental sciences*. 3. 38-45. 10.4103/0975-1475.85295.
- [13] <https://3dprint.com/20664/3d-printing-facial-reconstruct/>
- [14] Kundu A, Streed M, Galzi PJ, Johnson A. A detailed review of forensic facial reconstruction techniques. *Medico-Legal Journal*. 2021;89(2):106-116. doi:10.1177/0025817221989591
- [15] Richmond, R. and Pretty, I.A. (2007), Denture Marking—Patient Preference of Various Methods. *Journal of Forensic Sciences*, 52: 1338-1342. <https://doi.org/10.1111/j.1556-4029.2007.00586.x>